



PATIENT

Jackson Seasack

SPECIES

Canine

BREED

Westie

SEX

MN

AGE

12 years

WEIGHT

6.1 kg

INTERPRETED BY

Remo Lobetti, BVSc,
MMedVet (Med), PhD,
Dipl. ECVIM

IMAGING PERFORMED BY

Brent Crutchfield, DVM

HOSPITAL NAME

Treasure Coast Animal
Emergency

REFERRING VET

Dr Angela Cail

INVOICE

303743

DATE

1/10/23

PRESENTING CLINICAL SIGNS

History: Brain tumor, on prednisone.

Physical Examination: Abdominal pain.

Urinalysis: N/A.

CBC: N/A

Serum Biochemistry: Elevated bilirubin.

Radiographic Findings: N/A.

ULTRASONOGRAPHIC EXAMINATION OF THE ABDOMEN

Urinary System

Full urinary bladder with a normal thickness (0.2 cm) and appearance of the wall. Normal anechoic urine with no sediment or uroliths evident.

Normal proximal urethra and iliac blood vessels.

Normal iliac lymph nodes. Ureters not visualized.

Normal renal size (left 3.9 cm, right 3.7 cm) with increased echogenic appearance, some loss of cortico-medullary differentiation, and normal pelvis and capsule.

Reproductive System

Small hypoechogenic prostate (0.9 cm).

Adrenal Glands

Normal shape, echogenic appearance, position, and size. Left 0.39 cm, right 0.43 cm.

Spleen

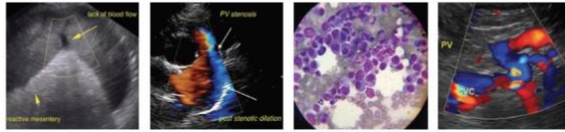
Normal size and echogenic appearance. Smooth homogenous parenchyma, regular curvilinear capsule, and normal vasculature. No evidence of inflammatory, neoplastic, infarction, or infiltrative changes noted.

Liver

Normal size, echogenic appearance, portal markings, and regular curvilinear capsule. No nodules or masses evident. Full gall bladder containing small amount of hyperechogenic sediment. Normal thickness (0.1 cm) and echogenic appearance of the gall bladder wall. Normal bile duct.

Gastrointestinal

Normal appearance of the gastro-esophageal junction, stomach, duodenum, small intestine, ileo-cecal junction, and colon with no loss of layering, normal wall thickness (jejunum 0.37 cm, colon 0.1 cm) and peristalsis, and no distension of the lumen.



PATIENT

Jackson Seasack

SPECIES

Canine

BREED

Westie

SEX

MN

AGE

12 years

WEIGHT

6.1 kg

Pancreas

Normal size and echogenic appearance. Regular capsule. Normal echogenic appearance of the mesentery and fat surrounding the pancreas.

Free Abdomen

No mesenteric lymphadenomegaly.
No ascites.

ULTRASONOGRAPHIC FINDINGS

Primary findings:

- None.

Secondary findings:

- Gall bladder sediment.
- Age-related renal changes.

INTERPRETATION OF THE FINDINGS & FURTHER RECOMMENDATIONS

In essence a normal ultrasound examination of the abdomen.

Further assessment that could be considered would urinalysis.

INTERPRETED BY

Remo Lobetti, BVSc,
MMedVet (Med), PhD,
Dipl. ECVIM

IMAGING PERFORMED BY

Brent Crutchfield, DVM

HOSPITAL NAME

Treasure Coast Animal
Emergency

REFERRING VET

Dr Angela Cail

INVOICE

303743

DATE

1/10/23



PATIENT

Jackson Seasack

SPECIES

Canine

BREED

Westie

SEX

MN

AGE

12 years

WEIGHT

6.1 kg

INTERPRETED BY

Remo Lobetti, BVSc,
MMedVet (Med), PhD,
Dipl. ECVIM

IMAGING PERFORMED BY

Brent Crutchfield, DVM

HOSPITAL NAME

Treasure Coast Animal
Emergency

REFERRING VET

Dr Angela Cail

INVOICE

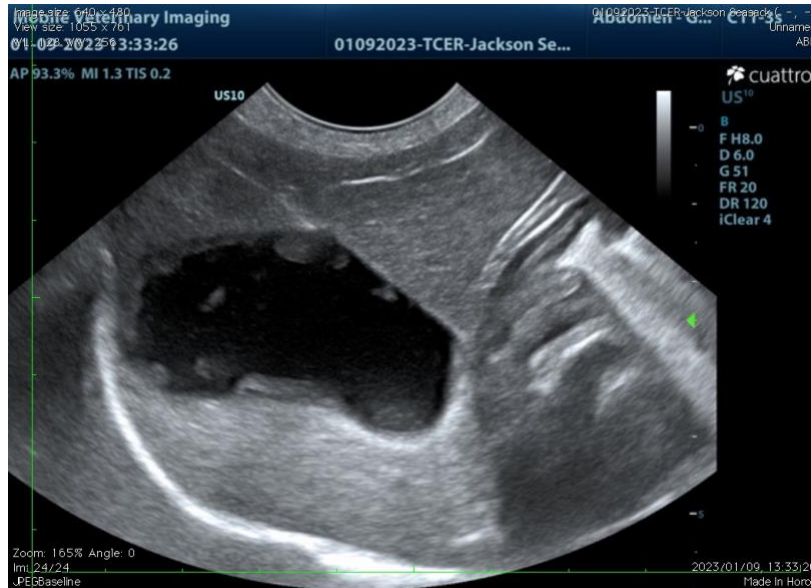303743

DATE

1/10/23

IMAGES

Gall bladder



The information and recommendations provided are based on the images presented by the referring veterinarian. No evaluation can be communicated regarding pathology that was not visible in the image/video clips provided.

Thank you for this referral. If the clinical or image interpretation does not parallel your findings or if I can be of any further assistance please contact me.

Remo Lobetti, BVSc, MMedVet (Med), PhD, Dipl. ECVIM (Internal Medicine)
rlobetti@mweb.co.za